

OFFICE OF THE MEDICAL EXAMINER
FLORIDA, DISTRICTS 7 & 24
VOLUSIA & SEMINOLE COUNTIES
1360 INDIAN LAKE ROAD, DAYTONA BEACH, FL 32124-1001


MEDICAL EXAMINER REPORT

Name	Martin, Trayvon	Medical Examiner #	12-24-043
Date of Birth	February 5, 1995	Date of Death (Found)	February 26, 2012
Age	17 Years	County	Seminole
Race	Black	Date of Exam	February 27, 2012
Sex	Male	Time of Exam	1030 Hours

FINAL DIAGNOSES AND FINDINGS

- I. Penetrating Gunshot Wound of the Chest
 - A. Entrance: Left chest, intermediate range
 - B. Path of the projectile: Skin, left anterior 5th intercostal space, pericardial sac, right ventricle of heart, and right lower lobe of lung
 - C. Direction of projectile: Directly, front to back
 - D. Exit: None; fragments of projectile recovered in pericardial sac and right pleural cavity
 - E. Associated injuries: Entrance wound; perforations of pericardial sac, right ventricle of heart, right lower lobe of lung with bilateral pleural hemorrhage
 - F. Postmortem radiograph: Metallic fragments of projectile identified

Cause of Death: Gunshot Wound of Chest
Manner of Death: Homicide
How incident occurred: Shot by another person


Shiping Bao, M. D.
Associate Medical Examiner

Date: 03/15/12

XC: State Attorney's Office
Sanford Police Department



"Accredited by the National Association of Medical Examiners"

Name **Martin, Trayvon**

ME # 12-24-043

**MEDICAL EXAMINER REPORT
REPORT OF AUTOPSY**

OFFICIALS PRESENT AT EXAMINATION

None.

EXTERNAL EXAMINATION

The body is secured in a blue body bag with Medical Examiner seal #0000517.

The body is viewed unclothed. The body is that of a normally developed, black male appearing the stated age of 17 years with a body length of 71 inches and body weight of 158 pounds. The body presents a medium build with average nutrition, normal hydration and good preservation. Rigor mortis is complete, and lividity is well developed and fixed on the posterior surfaces of the body. The body is cold to touch post refrigeration. Short black hair covers the scalp. The face is unremarkable. There is average body hair of adult-male-pattern distribution. The eyes are closed and have clear bulbar and palpebral conjunctivae. The irides are brown with white sclerae. There are no cataracts or arcus present. The pupils are equal at 5 millimeters. The orbits appear normal. The nasal cavities are unremarkable with an intact septum. The oral cavity presents natural teeth with fair oral hygiene. The ears are unremarkable with no hemorrhage in the external auditory canals. The neck is rigid due to postmortem changes, and there are no palpable masses. The chest is symmetrical. The abdomen is scaphoid.

The upper and lower extremities are equal and symmetrical and present cyanotic nail beds without clubbing or edema. There are no fractures, deformities or amputations present. The external genitalia present descended testicles and an unremarkable penis. The back reveals dependent lividity with contact pallor. The buttocks are traumatic, and the anus is intact. The integument is of normal color.

OTHER IDENTIFYING FEATURES

There are identification bands on the ankles.

SCARS

- 1 x ½ inch scar - right shoulder
- 1 x ½ inch scar - right hand

TATTOOS

- Symbol with letters - right arm
- Letters - left wrist

There are no other significant identifying features.

Name Martin, Trayvon

ME # 12-24-043

**MEDICAL EXAMINER REPORT
REPORT OF AUTOPSY**

EVIDENCE OF INJURY

Penetrating Gunshot Wound of the Chest:

The entrance wound is located on the left chest, 17½ inches below the top of the head, 1 inch to the left of the anterior midline, and ½ inch below the nipple. It consists of a ¼ inch diameter round entrance defect with soot, ring abrasion, and a 2 x 2 inch area of stippling. This wound is consistent with a wound of entrance of intermediate range.

Further examination demonstrates that the wound track passes directly from front to back and enters the pleural cavity with perforations of the left anterior fifth intercostal space, pericardial sac, right ventricle of the heart, and the right lower lobe of the lung. There is no wound of exit.

Three fragments of projectile are recovered. The lead core is recovered in the pericardial sac behind the right ventricle. Two fragments of the jacket are recovered in the right pleural cavity behind the right lower lobe of the lung.

The injuries associated with the wound: The entrance wound; perforations of left anterior fifth intercostal space, pericardial sac, right ventricle of the heart, right lower lobe of the lung with approximately 1300 milliliters of blood in the right pleural cavity and 1000 in the left pleural cavity; the collapse of both lungs.

Other injuries: There is a ¼ x ¼ inch small abrasion on the left fourth finger.

EVIDENCE OF RECENT MEDICAL TREATMENT

There is a cardiac monitor pad on the left flank.

EVIDENCE OF ORGAN AND/OR TISSUE DONATION

None.

INTERNAL EXAMINATION: The following excludes any previously described injuries.

BODY CAVITIES

The peritoneum is congested, smooth, glistening and essentially dry; devoid of adhesions or effusion. There is no scoliosis, kyphosis or lordosis present. The left and right diaphragms are in their normal location and appear grossly unremarkable.

Name Martin, Trayvon

ME # 12-24-043

**MEDICAL EXAMINER REPORT
REPORT OF AUTOPSY**

The subcutaneous fat measures 1.5 centimeters and is normally distributed, moist and bright yellow. The musculature of the chest and abdominal area is of normal color and texture.

NECK AND TONGUE

The neck presents an intact hyoid bone as well as the thyroid and cricoid cartilages. The larynx has unremarkable vocal cords and folds that appear widely patent without foreign material. The epiglottis is a characteristic plate-like structure without edema, trauma or pathological lesions. Both the musculature and the vasculature of the anterior neck are unremarkable. The trachea and spine are in the midline, and present no traumatic injuries or pathological lesions. The tongue is unremarkable.

CARDIOVASCULAR SYSTEM

The heart weighs 200 grams and there is no chamber hypertrophy or dilatation. The left ventricular wall is 1.1 centimeters and the right is 0.2 centimeters. The cardiac valves appear unremarkable. The coronary ostia are in the normal anatomical location leading into widely patent coronary arteries. Right dominant circulation is present. The endocardial surface is smooth without thrombi or inflammation. Sectioning of the myocardium presents no gross evidence of ischemic changes either of recent or remote origin. The aortic arch, along with the great vessels, appears grossly unremarkable.

RESPIRATORY SYSTEM

The lungs are collapsed and together weigh 410 grams. There are no gross pneumonic lesions or abnormal masses identified. The tracheobronchial tree and pulmonary arterial system are intact and grossly unremarkable. The pleural surfaces are pink and smooth with focal mild anthracosis.

HEPATOBIILIARY SYSTEM

The liver weighs 1110 grams and presents a brown, smooth, glistening surface. Focal patchy yellow discoloration, due to mild fatty metamorphosis, is present. On sectioning, the hepatic parenchyma is yellow-brown, homogeneous and congested. The unremarkable gallbladder contains approximately 8 milliliters of greenish bile. There is no cholecystitis or lithiasis. The biliary tree is patent. The pancreas presents a lobulated yellow cut surface without acute or chronic pancreatitis.

HEMOLYMPHATIC SYSTEM

The spleen weighs 100 grams and presents a gray-pink intact capsule and a dark red parenchyma. There is no lymphadenopathy. The thymus gland is involuted.

Name Martin, Trayvon

ME # 12-24-043

**MEDICAL EXAMINER REPORT
REPORT OF AUTOPSY**

GASTROINTESTINAL SYSTEM

The esophagus is intact with normal gastroesophageal junctions and without erosions or varices. The stomach is also normal without gastritis or ulcers, and contains 400 milliliters of gastric fluid with food particles. Loops of small and large bowel appear grossly unremarkable. The appendix is unremarkable.

UROGENITAL SYSTEM

The kidneys weigh 100 grams, and 110 grams, right and left, respectively. On sectioning, the cortex presents a normal thickness above the medulla. The renal columns of Bertin extend between the well-demarcated pyramids and appear unremarkable. The medulla presents normal renal pyramids with unremarkable papillae. The pelvis is of normal size and is lined by gray glistening mucosa. There are no calculi. The renal arteries and veins are normal. The ureters are of normal caliber lying in their course within the retroperitoneum and drain into an unremarkable urinary bladder containing approximately 75 milliliters of urine.

The external genitalia present an unremarkable penis without hypospadias, epispadias or phimosis. There are no infectious lesions or tumors noted. The descended testicles are of normal size encased within an intact and unremarkable scrotal sac. There are no abnormal masses or hernias on palpation. The prostate is of normal size and shape and sectioning presents two normal lateral lobes with a thin median lobe forming the floor of the unremarkable urethra. There are no gross pathological lesions.

ENDOCRINE SYSTEM

The thyroid gland is of normal size and shape and presents two well-defined lobes with a connecting isthmus and a beefy-brown cut surface. There are no goitrous changes or adenomas present. The adrenal glands are of normal size and shape. Sectioning presents no gross pathological lesions.

MUSCULOSKELETAL SYSTEM

The ribs, sternum, clavicles, pelvis and vertebral column have no recent fractures. The muscles are normally formed.

CENTRAL NERVOUS SYSTEM

The scalp is intact without contusions or lacerations. The calvarium is likewise intact without bony abnormalities or fractures. The brain weighs 1400 grams and presents moderate congestion of the leptomeninges. The overlying dura is intact and unremarkable. The cerebral hemispheres reveal a normal gyral pattern with severe global edema. The brainstem and cerebelli are normal in

Name Martin, Trayvon

ME # 12-24-043

**MEDICAL EXAMINER REPORT
REPORT OF AUTOPSY**

appearance with no evidence of cerebellar tonsillar notching. The circle of Willis is patent and presents no evidence of thrombosis or berry aneurysm. Upon coronal sectioning of the brain, the ventricular system is symmetrical and contains clear cerebrospinal fluid. There are no space-occupying lesions present. The spinal cord is not examined.

MICROSCOPIC EXAMINATION: One slide examined on March 15, 2012.

HEART: No diagnostic abnormality.

LUNGS: The partial collapse of tissues.

LIVER: No diagnostic abnormality.

TOXICOLOGY: See separate report from NMS Laboratories.

SB

End of Report

Office of the Medical Examiner, Volusia County

Name: UNIDENTIFIED #3,

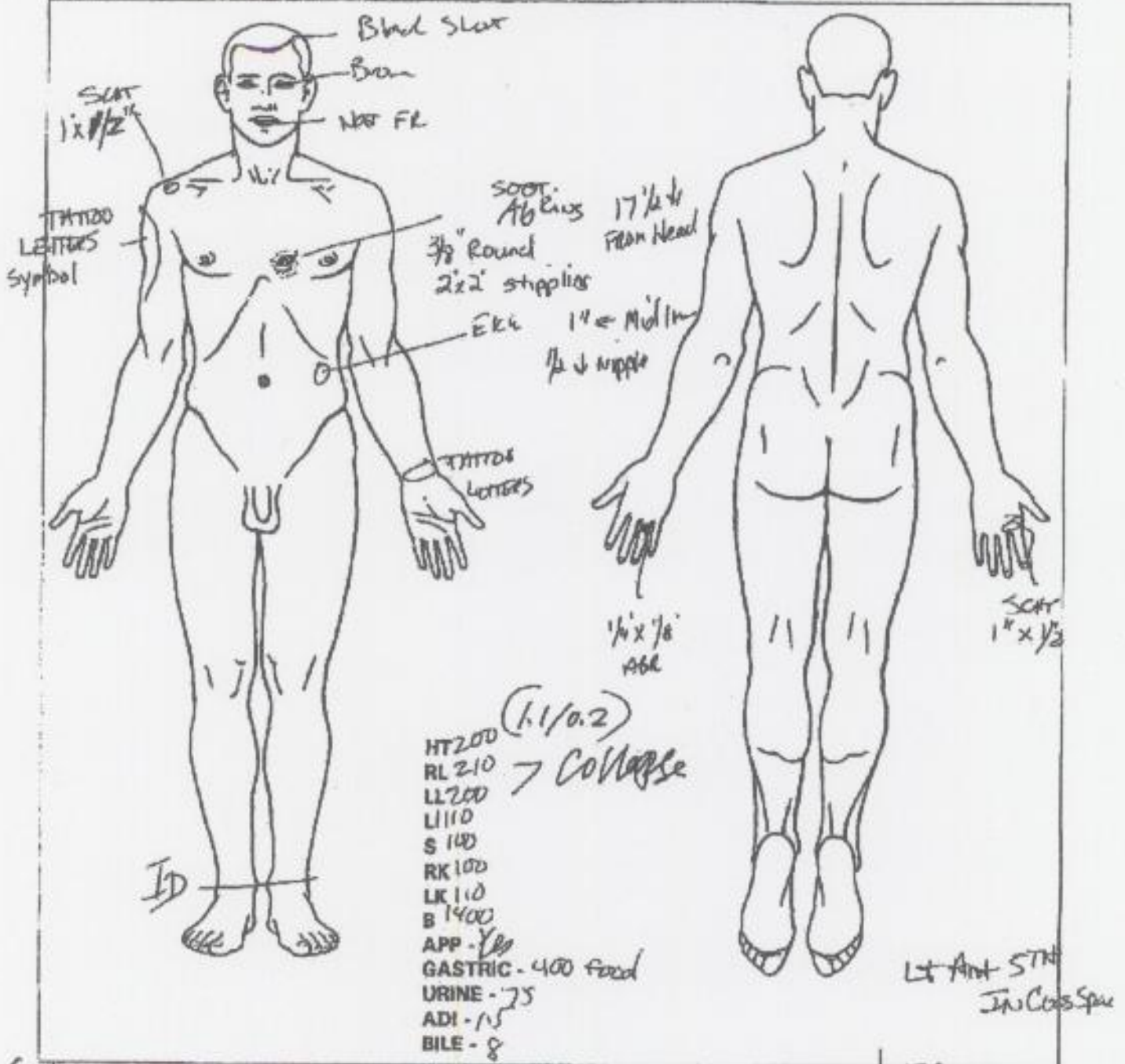
Case Number 2012-24043

Age:

Race: Black


Sex: Male

Date (DR.) 2/27/2012



Seal # 0000517

Rt Vein
Ant for Card Spec
Pro; Post of ET VENT, abax Sac



HT 71" WT 158 BMI 22 START TIME 10:30
 FROS x 2 Rt L Lobe being Recalled in Carth